

## IMMUNOHISTOCHEMICAL CORRELATION BETWEEN THE EXPRESSION OF VITAMIN D RECEPTOR (VDR) AND ESTROGEN RECEPTOR (ER) IN INVASIVE DUCTAL CARCINOMA TISSUES

<sup>1</sup>Fasogbon Samuel Ayobami <sup>2</sup>Ajileye Ayodeji Blessing <sup>3</sup>Abubakar Sharafudeen Dahiru.

<sup>1</sup>Public Health In-vitro Diagnostic Control Laboratory, Medical Laboratory Science Council of Nigeria, Lagos State, Nigeria - 234

<sup>2</sup>Department of Medical Laboratory Sciences, Afe Babalola University, Ado-Ekiti, Ekiti State, Nigeria - 234

<sup>3</sup>Department of Histopathology, Faculty of Medical Laboratory Science, Usmanu Danfodiyo University, Sokoto, Nigeria – 234

Received:25 Nov, 2017/Revised:4 Dec, 2017/Accepted:11 Dec, 2017

**ABSTRACT: Aim:** The study was carried out to determine the Immunohistochemical Correlation between the Expression of Vitamin D Receptor (VDR) and Estrogen Receptor (ER) in Invasive Ductal Carcinoma (IDC) tissues **Materials and Method:** A total number of fifty six (56) archived female breast Invasive Ductal Carcinoma tissue blocks were used. The tissue blocks were sectioned at not more than 2µm each. Haematoxylin and Eosin staining method and immunohistochemical staining technique using VDR and ER antibodies were done and the results were correlated. **Result and Discussion:** The results show that there is a significant difference ( $P<0.05$ ) found comparing the immunohistochemical expression of VDR with ER in IDC tissues. **Conclusion:** VDR antibody cannot be use in replacement of ER antibody in the immunohistochemical diagnosis of Invasive ductal carcinoma (IDC) of the breast.

**Keywords:** Vitamin D receptor (VDR), Estrogen receptor (ER), Invasive ductal carcinoma (IDC).

### INTRODUCTION:

Invasive ductal carcinoma (IDC), also known as infiltrating ductal carcinoma, is cancer that began growing in the duct and has invaded the fatty tissue of the breast outside of the duct. IDC is the most common form of breast cancer, representing 80 percent of all breast cancer diagnoses<sup>1</sup>. Breast cancer is the most frequent cancer among women, being a heterogeneous

disease, with distinct morphologies, metastatic behaviour and therapeutic response<sup>2</sup>. Approximately, 90% of breast cancer deaths are caused by local invasion and distant metastasis of tumor cells<sup>3</sup>. According to<sup>4</sup>, different types of this neoplasm exhibit variable histopathological and biological features, different clinical outcome and different response to systemic interventions. In fact, global gene-

#### **Corresponding author :**

**Fasogbon Samuel Ayobami**

**Public Health In-vitro Diagnostic Control Laboratory, Medical Laboratory Science Council of Nigeria, 8 Harvey Road, Yaba, Lagos State, Nigeria.**



expression analyses have provided an appealing molecular classification for breast carcinomas, which is highly associated with patients' prognosis<sup>5</sup>. In the last decade; a major effort has been made to better inform the choice of the systemic treatment for breast cancer patients.

The calcitriol receptor, also known as the vitamin D receptor (VDR) and also known as NR1H1 (nuclear receptor subfamily 1, group I, member 1), is a member of the nuclear receptor family of transcription factors<sup>6</sup>. Upon activation by vitamin D, the VDR forms a heterodimer with the retinoid-X receptor and binds to hormone response elements on DNA resulting in expression or transrepression of specific gene products. The VDR not only regulates transcriptional responses but also involved in microRNA-directed post transcriptional mechanisms<sup>7</sup>. In humans, the vitamin D receptor is encoded by the *VDR* gene<sup>8</sup>. Glucocorticoids are known to decrease expression of VDR, which is expressed in most tissues of the body and regulate intestinal transport of calcium, Iron and other minerals<sup>9</sup>. Also, it has recently been identified that VDR as an additional bile acid receptor alongside FXR and may function to protect gut against the toxic and carcinogenic effects some endobiotics<sup>10</sup>. Many studies have shown that there is a link between vitamin D and breast cancer. Women who have breast cancer tend to have low levels of vitamin D in their body. Researchers have found how vitamin D might have a role in breast cancer. Vitamin D receptors are found on the surface of a cell where they receive chemical signals. By attaching themselves to a receptor, these chemical signals direct a cell to do something, for example to act in a certain way, or to divide or die. There are vitamin D receptors in breast tissue, and vitamin D can bind to these receptors. These can oncogenes to die or stop growing, and can stop the cancer cells from spreading to other parts of

the body. Therefore, it is thought that vitamin D may help in protecting against breast cancer, by making cells in the breast smarter. However, the relationship between breast cancer and vitamin D is complex, not fully understood, and is still being studied<sup>11,12,13</sup>.

Breast cancer is the predominant malignancy where oncologists use predictive markers clinically to select treatment options, with steroid receptors having been used for many years. Immunohistochemistry has taken over as the major assay method used for assessing markers<sup>14</sup>. The advent of molecular technology has incorporated new biomarkers along with immunohistochemical and serum biomarkers. Immunohistochemical markers [Estrogen receptor (ER), Progesterone receptor (PR), and Human epidermal growth factor receptor 2 (HER2)] are often used to guide treatment decisions, to classify breast cancer into subtypes that are biologically distinct and behave differently, and both as prognostic and predictive factors<sup>14</sup>. The researcher therefore, has set out to correlate the immunohistochemical expression of VDR with ER in IDC tissues.

Breast cancer was already discovered to be associated with the steroid hormone estrogen more than a century ago and the discovery of the estrogen receptor (ER) provided us not only with a powerful predictive and prognostic marker, but also an efficient target for the treatment of hormone-dependent breast cancer with antiestrogens<sup>15</sup>. Vitamin D or calcitriol is also a steroid hormone in which evidence shows it participates in cell growth regulation, apoptosis, cell differentiation and it has been implicated in the suppression of cancer cell invasion, angiogenesis and metastasis<sup>16</sup>. Antiproliferative activity of 1,25-(OH)<sub>2</sub>-vitamin D<sub>3</sub> has been documented in breast carcinoma cells<sup>17</sup>. This study is therefore justified to know if VDR can give more relevance and valuable prognostic

information than ER in breast cancer; also because of the higher expensive nature of ER, there is need to know if VDR can be as a substitute for ER.

## **RESEARCH METHODOLOGY:**

### **Area of Study**

This study was carried out at Department of Histopathology, National Hospital Abuja, FCT, Nigeria. The Hospital serves most of the states of Nigeria and therefore serving a significant population of the region.

### **Ethical Consideration**

Approval for this research work was obtained from the Research Ethics Committee of National Hospital Abuja, FCT, Nigeria.

### **Sample Size**

A total of fifty six (56) samples were obtained. Sample size was determined using a formula by<sup>15</sup>.

### **Sample Collection/Histopathological Procedures**

Paraffin tissue blocks diagnosed of invasive ductal carcinoma of the female breast were used. The tissue blocks were sectioned at not more than 2 $\mu$ m each. Five sections were obtained from each block from which one (1) section was used for Haematoxylin and Eosin staining technique while two (2) sections were treated each with VDR and ER antibodies, while the other two (2) sections were used as negative and positive control.

### **Haematoxylin and Eosin Staining Technique**

The sections were taken to water, stained using Harris Haematoxylin for 5minutes, washed in tap water then differentiated in 1% acid alcohol for

few seconds. They were washed in tap water then blued in tap water for 10minutes. The sections were then counterstained in 1% Eosin for 1minutes. They were then washed in tap water, dehydrated, cleared and mounted using DPX<sup>16</sup>.

### **Immunohistochemical Technique**

The method used is the Avidin Biotin Complex (ABC) method and the antibodies used are manufactured by Novocastra. The antibody dilution factor used was 1:100 dilutions for all the antibody markers.

The processed tissues were sectioned at 2 $\mu$ m on the rotary microtome and placed on the hot plate at 70<sup>0</sup>C for at least 1hour. Sections were brought down to water by passing them in 2 changes of Xylene, then 3 changes of descending grades of alcohol and finally to water. Antigen retrieval was performed on the sections by heating them on a Citric Acid solution of pH 6.0 using the Microwave at 100<sup>0</sup>C for 15minutes. The sections were equilibrated gradually with cool water to displace the hot Citric Acid for at least 5min.

Peroxidase blocking was done on the sections by covering them with 3% hydrogen peroxide (H<sub>2</sub>O<sub>2</sub>) for 15min. Sections were washed with PBS and protein blocking was performed using avidin for 15min. Sections were washed with PBS and endogenous biotin in tissue was blocked using biotin for 15min. After washing with PBS sections were incubated with the respective diluted primary antibody antibody diluted 1:100 for 60 min. Excess antibodies were washed off with PBS and a secondary antibody (link) was applied on section for 15min. Sections were washed and the (label, in this case which is the Horseradish Peroxidase HRP) was applied on the sections for 15min. A working DAB solution is made up by mixing 1 drop (20 $\mu$ l) of the DAB chromogen to 1ml of the DAB substrate. This

working solution was applied on sections after washing off the HRP with PBS for at least 5min. The brown reaction began to appear at this moment especially for a positive target. Excess DAB solution and precipitate were washed with water. Sections were counterstained with Haematoxylin solution for at least 2min and blued briefly. Sections were dehydrated in alcohol, cleared in Xylene and mounted in DPX<sup>17</sup>.

### Immunohistochemical Analysis

Cells with specific brown colours in the cytoplasm, cell membrane or nuclei depending on the antigenic sites were considered to be positive. The Haematoxylin stained cells without any form of brown colours were scored negative. Non specific binding/brown artifacts on cells and connective tissue were disregarded<sup>17</sup>.

### Statistical Analysis

Photomicrograph was basically used for correlating the expression and where necessary, Paired T-test statistics method was used to analyse the data generated.

### RESULTS:

A total of fifty six (56) tissue blocks already diagnosed as invasive ductal carcinoma of the female breast (Age mean=46.4) were used for the study. The results were presented in tables and figures below:

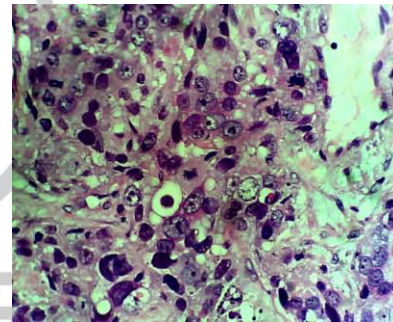
**TABLE 1: Expression of VDR and ER in invasive ductal carcinoma (IDC)**

PARAMETER	VDR	ER
POSTIVE	37	26
NEGATIVE	19	30
TOTAL	56	56

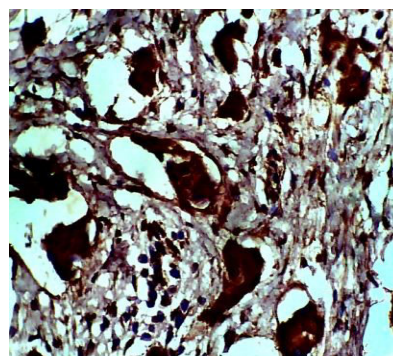
**TABLE 2: Correlation of immunohistochemical expression between VDR and ER in IDC tissues (paired t-test)**

Paired Samples Statistics	Mean	N	Std. Dev.	Std. Error Mean
Pair 1 ESTROGEN RECEPTOR	1.55	56	0.502	0.067
VITAMIN D RECEPTOR	1.34	56	0.478	0.064
Paired Samples Correlation		N	Correlation	Sig.
Pair 1 ESTROGEN RECEPTOR		56	-.115	0.398
VITAMIN D RECEPTOR				

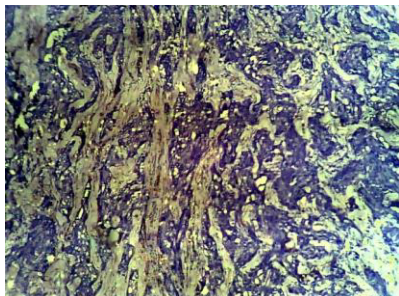
Mean ± SEM are 0.214 ± 0.098, therefore there is a significant difference between ER and VDR at a significant level (P) = 0.033 < 0.05, t55=2.192, Pearson(r) = 0.398



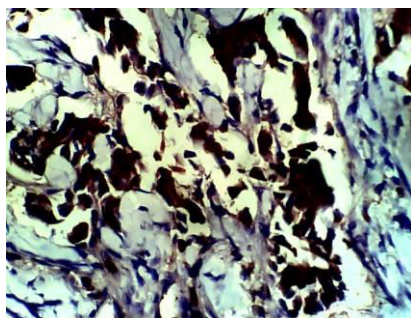
**Figure 1: Invasive Ductal Carcinoma (IDC) of the breast showing proliferation of epithelial cells appearing as atypical cells with marked nuclear enlargement and hyperchromasia (H and E; x400)**



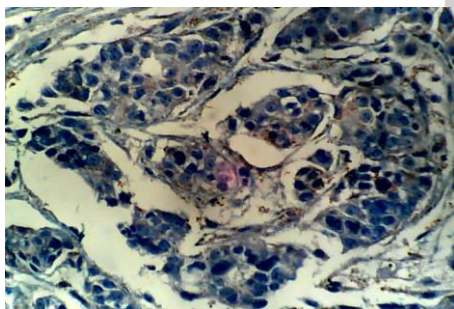
**Figure 2: Invasive Ductal Carcinoma (IDC) tissue showing Positive expression of Vitamin D Receptor (VDR) (x400)**



**Figure 3: Invasive Ductal Carcinoma (IDC) tissue showing Negative expression of Vitamin D Receptor (VDR) (x100)**



**Figure 4: Invasive Ductal Carcinoma (IDC) tissue showing Positive expression of ER in x400**



**Figure 5: Invasive Ductal Carcinoma (IDC) tissue showing Negative expression of ER (x400)**

### **DISCUSSION:**

There is a significant difference found; comparing VDR with ER expression in IDC tissues which indicate that VDR cannot be used over ER in the immunohistochemical diagnosis of IDC. This result is supported by earlier work done by<sup>18</sup> on VDR expression analyzed

immunohistochemically in breast cancer patients who reported that no statistically significant correlations were found comparing VDR expression with expression of estrogen receptors (ER) or progesterone receptors (PR), even with the proliferation marker Ki-67, with the tumor suppressor gene p53 or with the S-phase index. The findings indicate that VDR protein expression is not a prognostic factor in breast cancer<sup>18</sup>.

VDR shows the highest and strong positive expression on IDC tissues in this research which could indicate a link between Vitamin D receptor and breast cancer. This support a study carried out in which a strong VDR immunoreactivity was observed in breast cancer specimens, supporting the body of evidence that breast cancer may be a target for therapeutically applied vitamin D analogues<sup>19</sup>.

This also support a study carried out that said; there are vitamin D receptors in breast tissue, and vitamin D can bind to these receptors. This can cause oncogenes to die or stop growing, and can stop the cancer cells from spreading to other parts of the body. Therefore, it is thought that vitamin D may help in protecting against breast cancer<sup>11</sup>.

### **CONCLUSION:**

Breast cancer is heterogeneous disease, with distinct morphologies. The different types of this neoplasm exhibit variable histopathological and biological features, different clinical outcome and different response to systemic interventions.

On the basis of this study and review of relevant literature, VDR has no statistically significant correlations when compared with ER antibodies; but VDR highest rate of positivity in IDC tissues can indicate it link with breast cancer.

**REFERENCES:**

1. Johns Hopkins (2016): Invasive Ductal Carcinoma (IDC); [http://www.hopkinsmedicine.org/breast-center/breast\\_cancers\\_other\\_conditions/invasive\\_ductal\\_carcinoma.html](http://www.hopkinsmedicine.org/breast-center/breast_cancers_other_conditions/invasive_ductal_carcinoma.html) . Sited November, 2016
2. Ricardo, S., Vieira, A.F., Gerhard, R., Leitão, D., Pinto, R., Cameselle-Teijeiro, J. F., Milanezi, F., Schmitt, F., Paredes, J (2011): Breast cancer stem cell markers CD44, CD24 & ALDH: expression distinguishing intrinsic molecular subtype: *Journal of clinical pathology*; **64 (11)**: 937- 946.
3. Yifau, W., and Binhua, P.Z (2011): Epithelial-mesenchymal transition in breast cancer progression and metastasis: *Clinical journal of cancer*; **30 (9)**: 603-611.
4. Viale, G (2012): The current state of breast cancer classification: *Annual Oncology*; **23 (10)**:207-210.
5. Sotiriou, C., Neo, S.Y., McShane, L.M (2003): Breast cancer classification and prognosis based on gene expression profiles from a population-based study. *Proclaimed National Academic Science*; **100**:10393–10398.
6. Hosoi, T. (2002): Polymorphisms of vitamin D receptor gene. *Nippon Rinsho*. **60** Suppl 3: 106–110.
7. Uitterlinden AG, Fang Y, Van Meurs JB, Pols HA, Van Leeuwen JP (2004): "Genetics and biology of vitamin D receptor polymorphisms". *Gene* **338 (2)**: 143–156.
8. Norman A.W. (2007). "Minireview: vitamin D receptor: new assignments for an already busy receptor". *Endocrinology* **147 (12)**: 5542–5548.
9. Bollag W.B. (2007): Differentiation of human keratinocytes requires the vitamin d receptor and its coactivators. *Journal of Investment Dermatology* **127 (4)**: 748–750.
10. Salashor, S., and Woodgett, J.R. (2002): Links between AXIN and carcinogenesis; **58**:225-236
11. Rose A.A.N, Elser C, Ennis M. (2013): Blood levels of vitamin D and early stage breast cancer prognosis: a systematic review and meta-analysis. *Breast Cancer Resilience Treatment*; **141**:331-339.
12. Wang, D., Velez de-la-Paz OI, and Zhai JX, (2013): Serum 25-hydroxyvitamin D and breast cancer risk: a meta-analysis of prospective studies. *Tumor Biology*; 1-9.
13. Welsh J. (2012): Cellular and molecular effects of vitamin D on carcinogenesis. *Architecture, Biochemistry and Biophysics*; **523b**:107-114
14. Walker R. A. (2007): Immunohistochemical markers as predictive tools for breast cancer Department of Cancer Studies & Molecular Medicine, University of Leicester, Robert Kilpatrick Building, Leicester Royal Infirmary, *Journal of Clinical Pathology*; **61**:10.1136. Accepted 8 November 2007. Published Online First 23 November 2007
15. Naing, I., Winn, T. and Rusli, B.N. (2006). Practical issues in calculating the sample size for Prevalence studies. *Archives of orofacial Sciences.*; **1**:9-14.16.
16. Avwioro, O. G. (2014): Histochemistry and Tissue Pathology; Principle and Technique Third edition, page 133-168
17. Marc (2009): Standard Immunohistochemistry Staining Method;

18. Avidin Biotin Complex (ABC) Method. IHC world life science products and services.

[http://www.ihcworld.com/protocols/general\\_IHC/standard\\_abc\\_method.htm](http://www.ihcworld.com/protocols/general_IHC/standard_abc_method.htm)

[cited: 20th October, 2016]

19. Friedrich M, Villena-Heinsen C, Tilgen W, Schmidt W, Reichrat J, Axt-Flidner R. (2002): Vitamin D receptor (VDR) expression is not a prognostic factor in

breast cancer. *Anticancer Research* May-Jun; **22(3)**:1919-1924.

20. Friedrich M, Axt-Flidner R, Villena-Heinsen C, Tilgen W, Schmidt W, Reichrath J (2002): Analysis of vitamin D-receptor (VDR) and retinoid X-receptor alpha in breast cancer. *Journal of Histochemistry. Department of Gynecology and Obstetrics, University Hospital of Saarland, Homburg/Saar, Germany.* Jan-Feb; **34(1-2)**:35-40

**SOURCE OF FINANCIAL SUPPORT:** Nil

**CONFLICT OF INTEREST:** Authors declared no conflict of interest

- ✓ International Journal of Medical Laboratory Research (IJMLR) - Open Access Policy
- ✓ Authors/Contributors are responsible for originality of contents, true references, and ethical issues.
- ✓ IJMLR publishes all articles under Creative Commons Attribution- Non-Commercial 4.0 International License (CC)

**Cite of article:** Fasogbon SA, Ajileye AB, Abubakar SD. Immunohistochemical correlation between the expression of vitamin d receptor (vdr) and estrogen receptor (er) in invasive ductal carcinoma tissues. *Int. J. Med. Lab. Res.* 2017, 2(3): 26-32