

## A CASE OF NON-HEALING HERNIORRHAPHY: COMMON PROBLEM, UNCOMMON CAUSE

Rohini Sharma<sup>1</sup>, Binit Kumar Singh<sup>2</sup>, Chaitenya Verma<sup>2</sup>, Prahalad Kumar<sup>1</sup>, Pankaj Jorwal<sup>2</sup>

<sup>1</sup>National Tuberculosis Institute, Bangalore Karnataka

<sup>2</sup>Department of Medicine, All India Institute of Medical Sciences, New Delhi

Received: 7 Sep, 2017/Revised: 13 Sep, 2017/Accepted: 6 Nov, 2017

**ABSTRACT:** Post-operative wound infection, mesh site infection and delayed healing due to Nontuberculous mycobacteria (NTM) is scarcely reported in literature and hence they not recognized as a common cause for these. Generally, wound infections due to atypical mycobacteria shows delayed/non-healing because they do not respond to conventional antibiotics. Rapid identification of rapidly growing mycobacteria (RGM) like *M. abscessus* can be done by molecular methods using DNA probe hybridization. We report a case of non-healing herniorrhaphy due to wound infection by *M. abscessus* which was later identified by Line probe assay (CM/AS kit) and treated successfully. This case report emphasizes the importance of comprehensive evaluation of any non-healing postoperative wound by staining, cartridge based nucleic acid amplification test, liquid culture or by any other techniques extensively, in order to detecting an elusive cause such as *M. abscessus*.

**KEYWORDS:** Herniorrhaphy, Nontuberculous mycobacteria, Atypical mycobacteria

### INTRODUCTION:

Rapidly Growing Mycobacteria's (RGM's) are important opportunistic pathogens capable of causing severe infections in wounds and at surgical suture sites. *Mycobacterium abscessus* is a key member of this group responsible for quite a few of these cases. They can give rise to delayed or non-healing of wounds, disseminated disease and pulmonary infections in individuals. Nowadays, the nontuberculous mycobacteria (NTM), have gained significance clinically and are being actively searched for in such difficult to treat cases. At our centre, few cases of non-healing hernioplasty have been reported which

has drawn the attention of clinicians as well as microbiologists. Usually, in most cases the hernia is often associated with weakness at repair site caused by hematoma or seroma leading to delayed wound healing. Other causes of non-healing can be anatomical location, increased intra-abdominal pressure due to chronic cough, constipation, urinary obstruction, pregnancy or ascites. Use of unsterile surgical instruments and practices frequently results in non-healing; the latter can potentially be a pivotal source of NTM infection at the site.

#### **Corresponding Author:**

**Pankaj Jorwal**

Assistant Professor, Department of Medicine, Room no. 3070, Third floor,  
Teaching Block, All India Institute of Medical Sciences, Ansari Nagar, New  
Delhi- 110 029, India



## **CASE REPORT:**

We present the case of a 38-year-old male patient who presented with abdominal pain, localised swelling and pus discharge from infra-umbilical region, a site where he had previously undergone hernioplasty for an infra-umbilical hernia. Local examination revealed a swelling of about 2x1cm in size, which was soft, fluctuant and tender. It was present along the suture line of previous surgery and there was purulent discharge from it along with sinus formation. The patient was found to have recurrent drainage from one of the sinuses, with low-grade evening rise of temperature. Laboratory examination revealed haemoglobin: 9.9 g/dl, ESR: 57 mm in 1st hr, total lymphocyte count: 4800/mm<sup>3</sup> and fasting blood sugar: 96 mg/dl. His liver function tests, renal function tests and other investigations were all within the normal limit and Human Immunodeficiency Virus (HIV) status was non-reactive. Rest of the systemic examination was also unremarkable.

The patient underwent USG guided aspiration and aspirate was sent to Intermediate Reference Laboratory (IRL), Department of Medicine, All India Institute of Medical Sciences, New Delhi. The Ziehl Neelsen staining of the aspirate showed numerous Acid Fast Bacilli (AFB). The aspirate was further evaluated by cartridge based nucleic acid amplification test (CBNAAT) (Cepheid, Sunnyvale, US) and was found to be negative for presence of Mycobacterium Tuberculosis (Mtb), suggesting towards the possible presence of an NTM infection. The aspirate was then evaluated by liquid culture (MGIT-960) which reported it to be a rapid grower. The Immunochromatographic assay (ICA) was negative and liquid culture smear showed no cords. The positive culture from MGIT-960 was sub-cultured on solid culture media using Lowenstein Jensen (LJ) media culture technique to study about colony morphology and pigment production. Within a

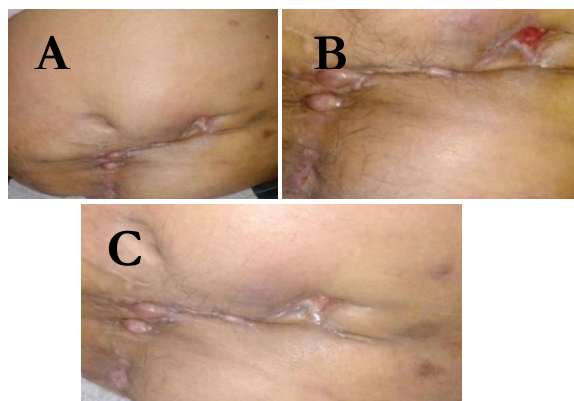
week, a luxuriant growth was observed along with pigmentation, which confirmed the presence of RGM. The species identification was performed by extracting the mycolic acid through solid culture to perform high performance liquid chromatography (HPLC), which later on revealed the presence of *M. abscessus*. The DNA extraction was done using Genolyse protocol for performing line probe assay (LPA) using CM/AS kit (Hain Lifescience, Nehren, Germany) for the identification of NTM species. The final outcome by LPA was also *M. abscessus*. Both, HPLC and LPA identified the organism as *M. abscessus*. The 16S rRNA gene sequencing using internal transcribed spacer region (ITS), was performed and it also identified the organism as *M. abscessus*. The sequences were then submitted to NCBI and a Gene Bank accession (KX263280.1) number was obtained.

The patient was initiated on Clarithromycin 500mg bd, Ethambutol 1200 mg bd, and Rifabutin 300mg bd daily. The duration of treatment was 9 months. The patient responded to the treatment and is under regular follow up.

Being ever-present in nature, NTMs are found in both clean and dirty water. It can be easily transmitted by inhalation of dust, dirt and by intake of infected water or by skin injection, they usually cause problems in immunocompromised individuals, patients with organ transplantation or in postoperative surgical wounds. Their spread from one person to another is uncommon<sup>1</sup>. The postoperative wound infection by nontuberculous mycobacteria can be the cause of mortality if they are not diagnosed and treated in time<sup>2</sup>.

In the beginning, the postoperative wound appears to be progressing satisfactorily, but soon it becomes erythematous and gradually it changes into a pus discharging sinus. Low-grade fever, along with mild pain at local site and difficulty in walking are common complains. In

chronic non-healing lesions, first of all a mycobacterium infection must be ruled out, which can present in a similar way. NTM infections are responsible of approximately 80% of the cases of late postoperative wound healing<sup>3</sup>. Species identification techniques using GenoType kits uses both amplification and hybridization techniques and is pretty robust<sup>4</sup>, with the advantage of being able to sense diverse infections within a limited duration(6 hours). The major limitations are cost and dependence on a fully-grown culture<sup>4</sup>. The other technique for species identification of NTM is INNO-LiPA Mycobacteria v2 assay, it permits the recognition of 16 classes of mycobacteria, including RGM<sup>5</sup>. Under the Runyon classification, *M.abscessus* is grouped under RGM and is well known to cause skin and soft tissue infections<sup>6</sup> but there is paucity of data regarding in-vitro antimicrobial susceptibility and clinical response. However, some of the published data report good response in macrolide-based regimens for non-pulmonary *M.abscessus* infections. On the other hand, there are few reports of a new genotypic mutations in some of the RGM's, caused by novel 'erm 41' gene which has inducible resistance therefore one should really be cautious when using macrolides in a reported RGM infection and insist on species identification with susceptibility testing as far as



**Figure 1(A-C): Postsurgical mesh-related NTM infection by *M. abscessus***

possible<sup>6,7,8</sup>. While treating any non-healing surgical wound, NTM infections should always be looked for and proactive communication to the lab for the same can be lifesaving. Our national tuberculosis program, RNTCP also needs to look at NTM's as an important entity responsible for persistent sputum positivity in previously treated individuals. There is an unmet need to develop species specific diagnostic and treatment protocols for NTM's

This case report reveals the importance of performing all-inclusive in-depth analysis including ZN smear, CBNAAT, liquid culture, solid culture and other techniques for identification of a concealed NTM infection. Suspicion of NTM infection should be high in wounds showing late healing and not responding to anticipated course of action with adequate antibiotic therapy. Early analysis and accurate identification can help the clinicians in the initiating appropriate therapy and prevent complications.

#### **REFERENCES:**

1. Nag VL, Rahman W, Maurya AK, Kumar M, Kumar, Dhole TN. Non healing post-surgical wound due to NTM (*Mycobacterium fortuitum*) in immunocompetent patient treated by conservatively in tertiary care centre. J Biomed Sci and Res. 2010;2:227-30
2. Shah AK, Gambhir RPS, Hazra N, R Katoch. Non tuberculous mycobacteria in surgical wounds- a rising cause of concern?, Indian J Surg. 2010; 72:206-210 DOI: 10.1007/s12262-010-0057-9
3. Kalita JB, Rahman H, Baruah KC. Delayed postoperative wound infections Due to non-tuberculous *Mycobacterium*. Indian J Med Res. 2005; 122:535-39.

4. Couto I, Machado D, Viveiros M, Rodrigues L, Amaral L. Identification of nontuberculous Mycobacteria in clinical samples using molecular methods: a 3-year study. Clin Microbiol Infect. 2010; 16:1161–64.
5. García-Agudo L, Jesús I, Rodríguez-Iglesias M, García-Martos P. Evaluation of Inno-lipa Mycobacteria v2 assay for identification of rapidly growing Mycobacteria. Brazilian Journal of Microbiology. 2011;42:1220–26.
6. Caplivski D, Scheld WM. Consultations in infectious diseases: a case based approach to diagnosis and management. New York: Oxford University Press; 2012:274–6
7. Griffith DE, Aksamit T, Brown-Elliott BA, et al. An official ATS/IDSA statement: diagnosis, treatment, and prevention of non-tuberculous mycobacterial diseases. Am J Respir Crit Care Med 2007;175:367–416
8. Mandell GL, Bennett EB, Dolin R. Principles and practice of infectious diseases. 7th edn Philadelphia: Churchill Livingstone Elsevier, 2010:3194–95

---

**CONFLICT OF INTEREST:** Authors declared no conflict of interest

**SOURCE OF FINANCIAL SUPPORT:** Nil

- ✓ International Journal of Medical Laboratory Research (IJMLR) - Open Access Policy
- ✓ Authors/Contributors are responsible for originality of contents, true references, and ethical issues.
- ✓ IJMLR publishes all articles under Creative Commons Attribution- Non-Commercial 4.0 International License (CC BY-NC). <https://creativecommons.org/licenses/by-nc/4.0/legalcode>

**Cite of article:** Sharma R, Singh BK, Verma C, Kumar P, Jorwal P. A case of non-healing herniorrhaphy: common problem, uncommon cause. Int. J. Med. Lab. Res. 2017, 2(3): 63-66.

---